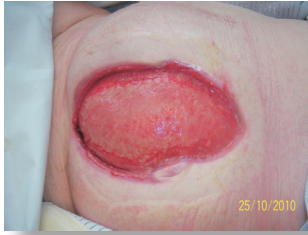
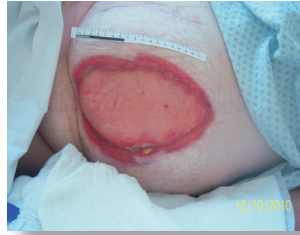
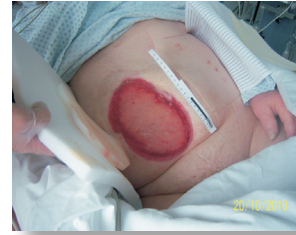## Patient with hemicolectomy



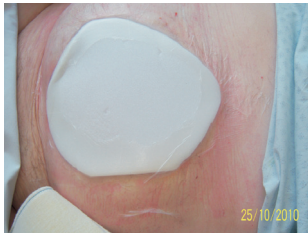5th day of treatment: change on second and 5th day.



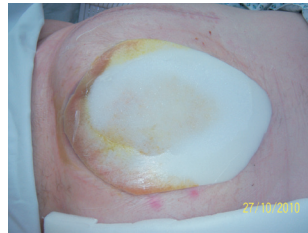
Complicated progression after hemicolectomy. Meanwhile haemodialysis. Abdominal occlusion with vicryl mesh. At the outset: dressing with wet abdominal bandages dampened 2 - 3 x daily and secured with an abdominal fascia.



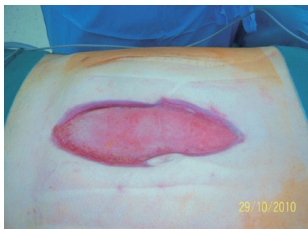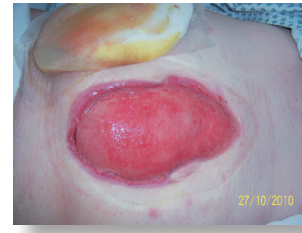Start MOMOSAN white



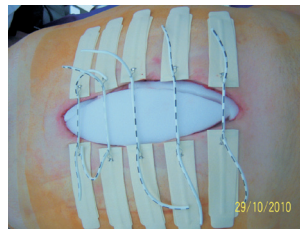The edges of the bottom layer were attached with plastic film for fixation.



Day 7: dressing change after two days. The wound remains wet.



Day 9: operative mobilisation of the skin edges and application of a dynamic suture with elastomers.



MOMOSAN white as wound dressing.