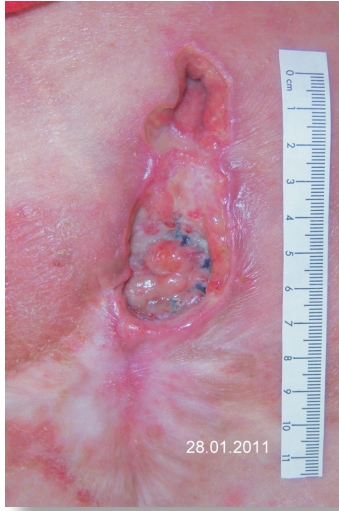
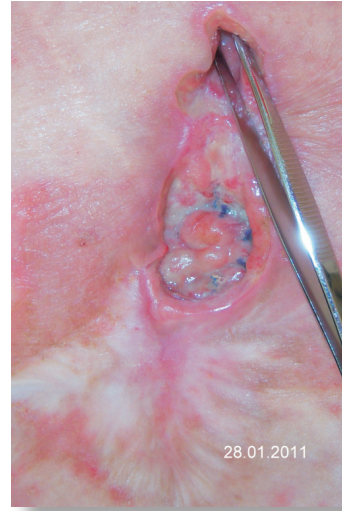
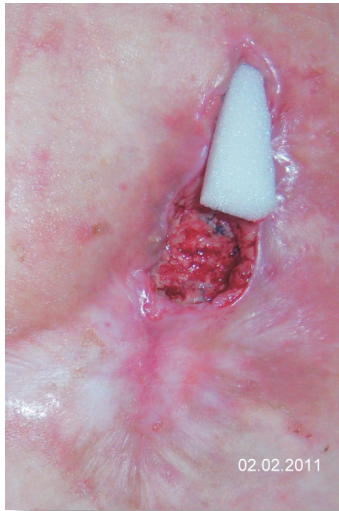**Patient** with delayed abscess and fistula tract after incisional hernia repair



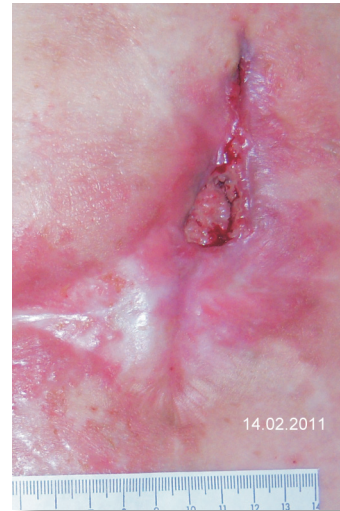
Delayed abscess with abdominal fistula after incisional hernia repair with mesh implantation. Operative fistula excision, exposed polypropylene mesh.



Probe-patent fistula



Treatment with  
**MOMOSAN** white



Diagnosis two weeks after the surgery. Fully granulated over the mesh. Fistula tract closed.