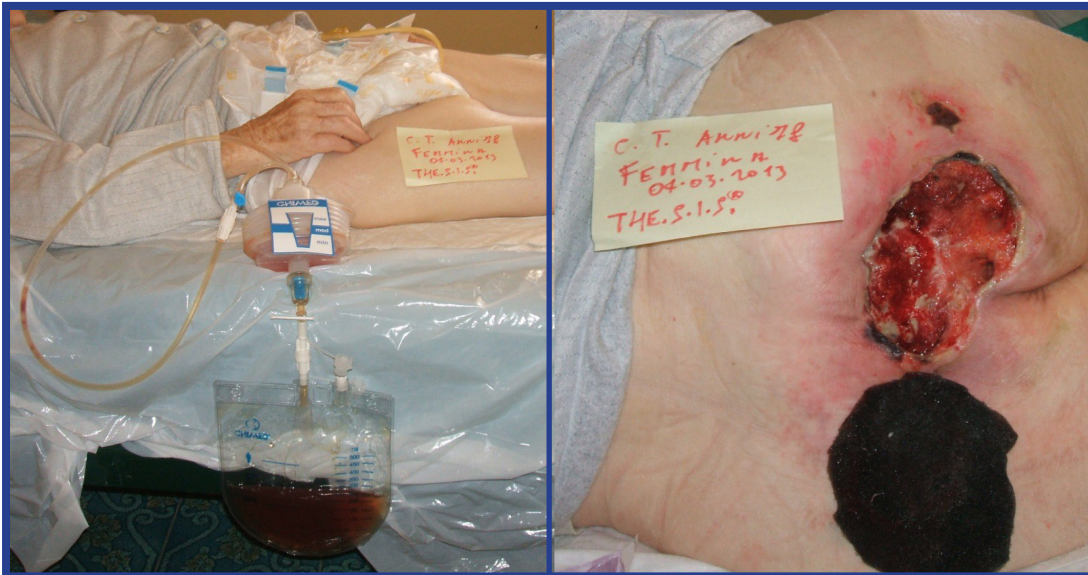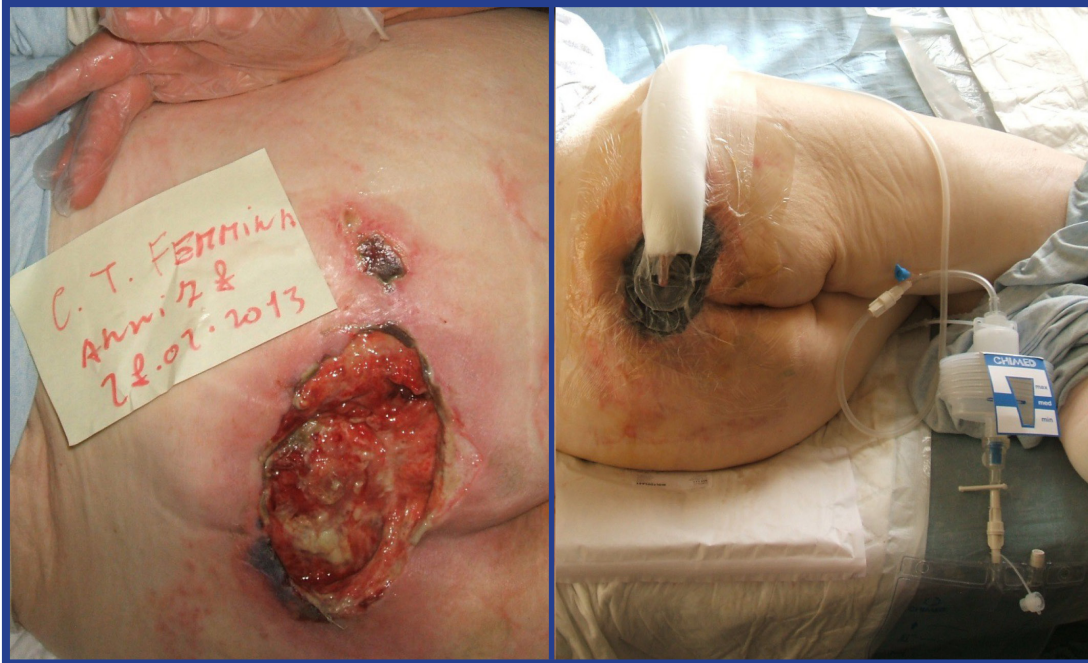


Patient: 78 years, decubitus stage IV



Result after 4 days of treatment with
MOMOSAN® black and MOMOSAN® white
in connection with (The.s.is.) – non-motorised NPWT system

MOMOSAN®
in connection with NPWT

Application report