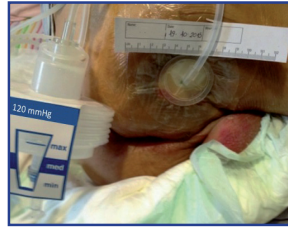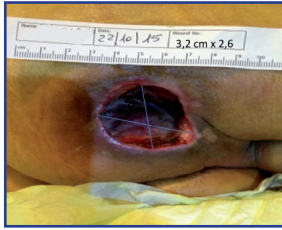

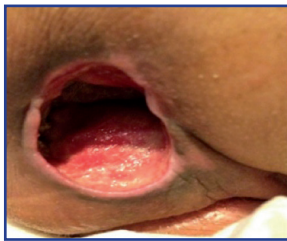
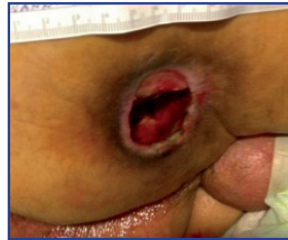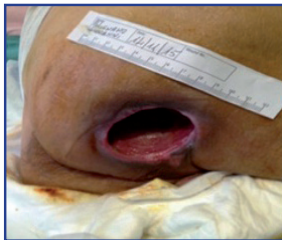86 years, Dementia, Parkinson's disease, respiratory insufficiency



Start of treatment with **MOMOSAN** black in connection with NPWT (THESES).



Examination after 5 days
 Outstanding course of treatment, excellent cleansing, start of granulation tissue formation, outstanding management of the surrounding skin



After a further 11 days, good filling of the wound bed, outstanding skin management, reactivation of the edges

Summary:

Considering the treatment of patients in very critical states, the result is to be considered outstanding.

MOMOSAN white and **MOMOSAN** black are ideally suited for achieving best results in connection with NPWT systems.

MOMOSAN[®]

Application report with NPWT