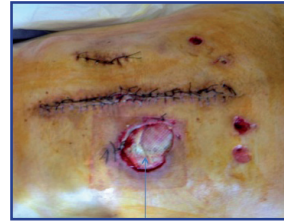
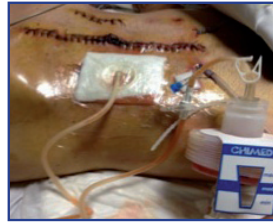


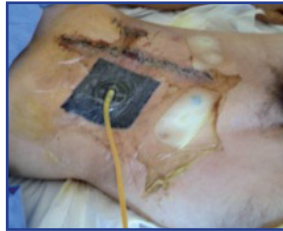
Application of MOMOSAN white (24x16x-1cm) and placing of the NPWT („THESES“) after the surgery.



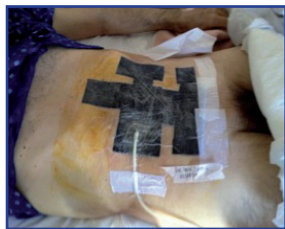Examination after 4 days.



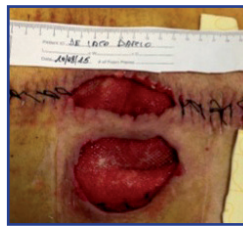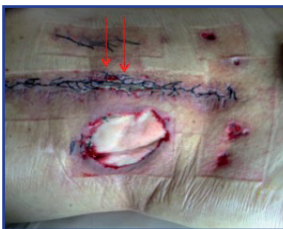3rd treatment with MOMOSAN black



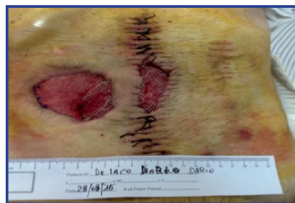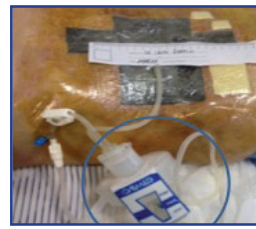4th treatment after a further 4 days



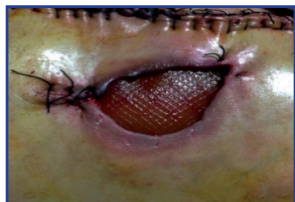
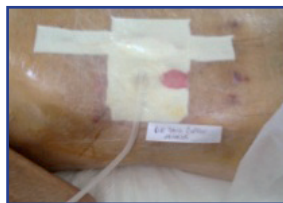6th treatment after a further 5 days



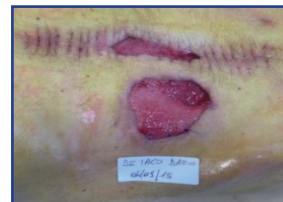Examination after a further 7 days, wound dehiscence cleansed, very good granulation tissue formation.



Examination after a further 8 days, follow-up treatment with MOMOSAN white in connection with NPWT („THESES“).



before



after

Outstanding healing progress, comparison after 50 days.

Summary:

Considering the treatment of patients in very critical states, the result is to be considered outstanding.

MOMOSAN white and MOMOSAN black are ideally suited for achieving best results in connection with NPWT systems.

MOMOSAN®

Application report with NPWT

Crohn's disease, colostoma, peritonitis

Patient: