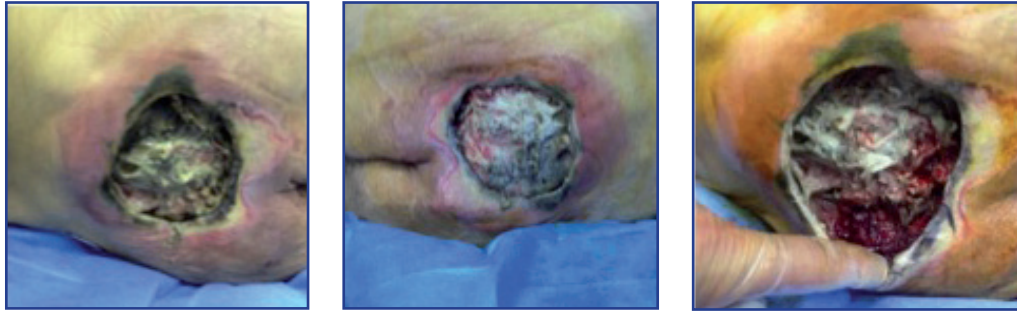
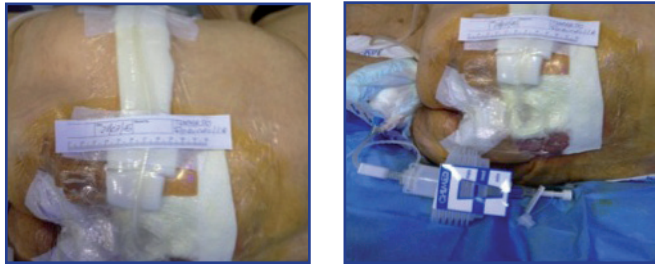


Septic, hyperpyrexia, coma after respiratory failure,  
 diabetic, suffering from cardiac disease

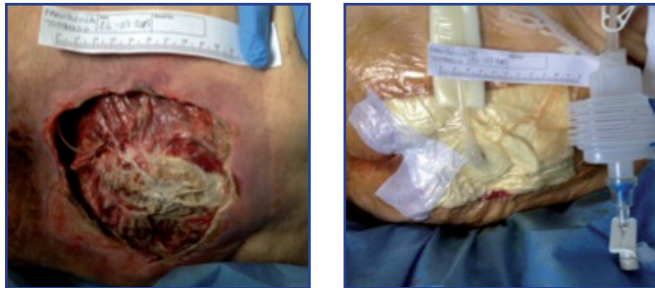**Patient:**



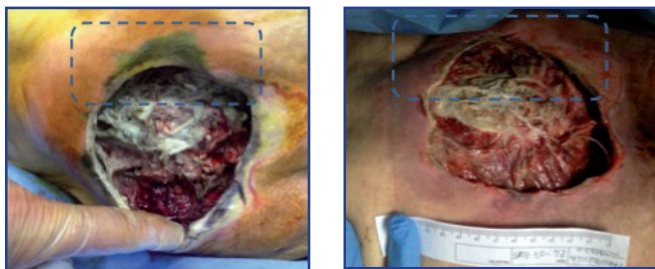
Removal of the necrotic tissue and start of an antibiotic therapy (Cefazolin).



Application of **MOMOSAN** white in connection with NPWT (,THESES')



Removal after 3 days for examination.  
 Outstanding exudate management with tissue renewal.



before

after

**Summary:**

Considering the treatment of patients in very critical states, the result is to be considered outstanding.

**MOMOSAN** white and **MOMOSAN** black are ideally suited for achieving best results in connection with NPWT systems.

**MOMOSAN®**

Application report with NPWT